

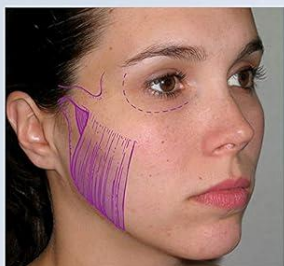TEST BANK

Illustrated Anatomy of the Head and Neck

Margaret J. Fehrenbach, Susan W. Herring

5th Edition

MARGARET J. FEHRENBACH
SUSAN W. HERRING



Illustrated Anatomy OF THE **Head** AND **Neck**

5th
EDITION

ELSEVIER



EVOLVE STUDY RESOURCES FREE WITH TEXTBOOK PURCHASE
EVOLVE.ELSEVIER.COM

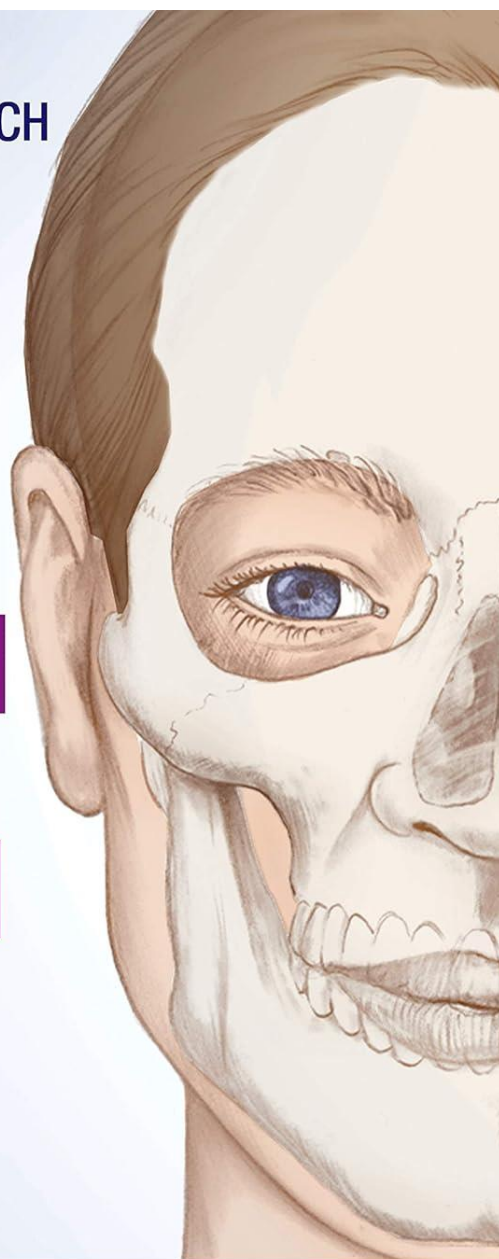


Table of Contents

1. Introduction to Head and Neck Anatomy
2. Surface Anatomy
3. Skeletal System
4. Muscular System
5. Temporomandibular Joint
6. Vascular System
7. Glandular Tissue
8. Nervous System
9. Anatomy of Local Anesthesia
10. Lymphatic System
11. Fascia and Spaces
12. Spread of Dental Infection

Chapter 01: Introduction to Head and Neck Anatomy

Fehrenbach: Illustrated Anatomy of the Head and Neck, 5th Edition

MULTIPLE CHOICE

1. Which surface of the body is visualized by the clinician when performing an extraoral examination of the patient's eyes?
 - a. Anterior
 - b. Posterior
 - c. Superior
 - d. Lateral

ANS: A

	Feedback
A	The patient's eyes are visualized on the anterior surface of the patient's body.
B	The patient's eyes would NOT be easily visualized on the posterior of the patient's body.
C	The patient's eyes would NOT be easily visualized on the superior surface of the patient's body.
D	The patient's eyes would NOT be easily visualized on the lateral surface of the patient's body.

DIF: Comprehension

REF: p. 3

OBJ: 2

TOP: CDA: General Chairside, I. B. Preliminary Physical Examination

MSC: NBDHE, Scientific Basis for Dental Hygiene Practice, 1.1.1 Head and Neck Anatomy

2. Which of the following is CORRECT concerning the sagittal plane of the body?
 - a. Parallel to the median plane
 - b. Parallel to the frontal plane
 - c. Parallel to the horizontal plane
 - d. Parallel to the coronal plane

ANS: A

	Feedback
A	A sagittal plane is parallel to the median plane.
B	A sagittal plane is NOT parallel to the frontal plane but perpendicular.
C	A horizontal plane is perpendicular to the median plane. A sagittal plane is parallel to the median plane. Thus a horizontal plane is perpendicular to a sagittal plane.
D	A sagittal plane is NOT parallel to the coronal plane but perpendicular.

DIF: Recall

REF: p. 3

OBJ: 1

TOP: CDA: General Chairside, I. A. Demonstrate understanding of basic oral and dental anatomy, physiology, and development

MSC: NBDHE, Scientific Basis for Dental Hygiene Practice, 1.1 Anatomy

3. When a patient is in anatomic position, what is the surface of the palms of the hand considered?
- Anterior
 - Lateral
 - Medial
 - Posterior

ANS: A

	Feedback
A	The palms of the hands in anatomic position are facing toward the front and are anterior (or ventral).
B	The palms of the hands in anatomic position are NOT facing lateral or away from the median plane but are facing toward the front and are anterior (or ventral).
C	The palms of the hands in anatomic position are NOT facing medial or toward the median plane but are facing toward the front and are anterior (or ventral).
D	The palms of the hands in anatomic position are NOT facing toward the posterior or back of the body but are facing toward the front and are anterior (or ventral).

DIF: Recall REF: p. 3 OBJ: 2

TOP: CDA: General Chairside, I. B. Preliminary Physical Examination

MSC: NBDHE, Provision of Clinical Dental Hygiene Services, 1.0 Assessing Patient Characteristics

4. What is the anatomic relationship of the right arm to the left leg?
- Sagittal
 - Contralateral
 - Ipsilateral
 - Midsagittal

ANS: B

	Feedback
A	The two legs are contralateral to each other. Sagittal describes a plane of division of the body created by an imaginary plane parallel to the median plane.
B	Contralateral structures are located on the opposite side of the body, which is the anatomic relationship of the right arm to the left leg.
C	Ipsilateral refers to structures on the same side of the body; in contrast, the two legs are contralateral to each other and thus are located on the opposite side of the body.
D	The two legs are contralateral to each other. Midsagittal describes a plane that divides the body into right and left halves.

DIF: Comprehension REF: p. 3 OBJ: 2

TOP: CDA: General Chairside, I. A. Demonstrate understanding of basic oral and dental anatomy, physiology, and development

MSC: NBDHE, Scientific Basis for Dental Hygiene Practice, 1.1 Anatomy

5. What is the anatomic relationship of the muscles to the skin?

- a. Anterior
- b. External
- c. Deep
- d. Superficial

ANS: C

	Feedback
A	Muscles are deep to the skin.
B	Muscles are deep to the skin.
C	Muscles are located inward, away from the body surface, deep to the skin.
D	Muscles are deep to the skin.

DIF: Comprehension

REF: p. 3

OBJ: 2

TOP: CDA: General Chairside, I. A. Demonstrate understanding of basic oral and dental anatomy, physiology, and development

MSC: NBDHE, Scientific Basis for Dental Hygiene Practice, 1.1 Anatomy

6. What is the anatomic relationship of the shoulders to the hips?
- a. Deep
 - b. Medial
 - c. Inferior
 - d. Superior

ANS: D

	Feedback
A	The shoulders are superior to the hips.
B	The shoulders are superior to the hips.
C	The shoulders are superior to the hips.
D	The shoulders are superior to or closer to the head than the hips.

DIF: Comprehension

REF: p. 3

OBJ: 2

TOP: CDA: General Chairside, I. A. Demonstrate understanding of basic oral and dental anatomy, physiology, and development

MSC: NBDHE, Scientific Basis for Dental Hygiene Practice, 1.1 Anatomy

7. Which of the following is meant by the term “ventral”?
- a. Back of an area of the body
 - b. Front of an area of the body
 - c. Inner side of an area of the body
 - d. Outer side of an area of the body

ANS: B

	Feedback
A	The back of an area of the body is referred to as the posterior surface.
B	The front of an area of the body is referred to as the ventral surface.
C	The inner side of an area of the body, away from the body surface, is referred to as deep.
D	The outside of an area of the body, toward the surface, is referred to as

	superficial.
--	--------------

DIF: Recall REF: p. 3 OBJ: 1
TOP: CDA: General Chairside, I. A. Demonstrate understanding of basic oral and dental anatomy, physiology, and development
MSC: NBDHE, Scientific Basis for Dental Hygiene Practice, 1.1 Anatomy

8. Which of the following describes a patient's eyes when they are in anatomic position?
- a. Closed tightly
 - b. Looking toward the lateral
 - c. Looking toward the medial
 - d. Looking straight forward

ANS: D

Feedback	
A	The patient's eyes in anatomic position are open and look forward.
B	The patient's eyes in anatomic position are open and look forward.
C	The patient's eyes in anatomic position are open and look forward.
D	The patient's eyes in anatomic position are open and look forward.

DIF: Recall REF: p. 2 OBJ: 2
TOP: CDA: General Chairside, I. B. Preliminary Physical Examination
MSC: NBDHE, Scientific Basis for Dental Hygiene Practice, 1.1.1 Head and Neck Anatomy

9. What is the anatomic relationship of the maxillary arch to the mandibular arch?
- a. Deep
 - b. Inferior
 - c. Superior
 - d. Superficial

ANS: C

Feedback	
A	The maxillary arch is superior to the mandibular arch. Deep refers to structures that are located away from the body surface.
B	The maxillary arch is superior to the mandibular arch. Inferior refers to surfaces closer to the feet or that face toward the feet.
C	The maxillary arch is superior to the mandibular arch.
D	The maxillary arch is superior to the mandibular arch. Superficial refers to structures located toward the surface of the body.

DIF: Comprehension REF: p. 3 OBJ: 2
TOP: CDA: General Chairside, I. A. Demonstrate understanding of basic oral and dental anatomy, physiology, and development
MSC: NBDHE, Scientific Basis for Dental Hygiene Practice, 1.1.1 Head and Neck Anatomy

10. What is the anatomic relationship of the teeth located in the front of the mouth to the teeth located in the back of the mouth?
- a. Anterior
 - b. Medial

- c. Posterior
- d. Superficial

ANS: C

	Feedback
A	Teeth located in the back of the mouth are considered posterior. Teeth located in the front of the mouth are considered anterior.
B	Medial refers to structures located closer to the median plane.
C	Teeth located in the back of the mouth are considered posterior to teeth located in the front of the mouth, which are considered anterior.
D	Superficial refers to structures located closer to the surface of the body.

DIF: Comprehension

REF: p. 3

OBJ: 2

TOP: CDA: General Chairside, I. A. Demonstrate understanding of basic oral and dental anatomy, physiology, and development

MSC: NBDHE, Scientific Basis for Dental Hygiene Practice, 1.1.2 Dental Anatomy

11. The inner side of the wall of a hollow structure is referred to as internal. In contrast, the outer side of the wall of a hollow structure is external.
- a. Both statements are true.
 - b. Both statements are false.
 - c. The first statement is true; the second is false.
 - d. The first statement is false; the second is true.

ANS: A

	Feedback
A	Both statements are true. The inner side of the wall of a hollow structure is referred to as internal. The outer side of the wall of a hollow structure is external.
B	Both statements are true. The inner side of the wall of a hollow structure is referred to as internal. The outer side of the wall of a hollow structure is external.
C	Both statements are true. The inner side of the wall of a hollow structure is referred to as internal. The outer side of the wall of a hollow structure is external.
D	Both statements are true. The inner side of the wall of a hollow structure is referred to as internal. The outer side of the wall of a hollow structure is external.

DIF: Recall

REF: p. 3

OBJ: 1

TOP: CDA: General Chairside, I. A. Demonstrate understanding of basic oral and dental anatomy, physiology, and development

MSC: NBDHE, Scientific Basis for Dental Hygiene Practice, 1.1 Anatomy

12. What is another term for a *transverse section*?
- a. Vertical section
 - b. Horizontal section
 - c. Anterior section
 - d. Posterior section

ANS: B

	Feedback
--	----------

A	The transverse section or horizontal section is a division through a horizontal plane.
B	The transverse section or horizontal section is a division through a horizontal plane.
C	The transverse section or horizontal section is a division through a horizontal plane.
D	The transverse section or horizontal section is a division through a horizontal plane.

DIF: Recall REF: p. 3 OBJ: 1
TOP: CDA: General Chairside, I. A. Demonstrate understanding of basic oral and dental anatomy, physiology, and development
MSC: NBDHE, Scientific Basis for Dental Hygiene Practice, 1.1 Anatomy

13. An area closer to the median plane is considered to be distal, and an area farther from the median plane is considered proximal.
- Both statements are true.
 - Both statements are false.
 - The first statement is true; the second is false.
 - The first statement is false; the second is true.

ANS: B

Feedback	
A	Both statements are false. An area closer to the median plane is considered to be proximal, and an area farther from the median plane is considered distal.
B	Both statements are false. An area closer to the median plane is considered to be proximal, and an area farther from the median plane is considered distal.
C	Both statements are false. An area closer to the median plane is considered to be proximal, and an area farther from the median plane is considered distal.
D	Both statements are false. An area closer to the median plane is considered to be proximal, and an area farther from the median plane is considered distal.

DIF: Recall REF: p. 3 OBJ: 1
TOP: CDA: General Chairside, I. A. Demonstrate understanding of basic oral and dental anatomy, physiology, and development
MSC: NBDHE, Scientific Basis for Dental Hygiene Practice, 1.1 Anatomy

14. Structures on the same side of the body are considered ipsilateral. Structures on the opposite side of the body are considered contralateral.
- Both statements are true.
 - Both statements are false.
 - The first statement is true; the second is false.
 - The first statement is false; the second is true.

ANS: A

Feedback	
A	Both statements are true. Structures on the same side of the body are considered ipsilateral. Structures on the opposite side of the body are considered

	contralateral.
B	Both statements are true. Structures on the same side of the body are considered ipsilateral. Structures on the opposite side of the body are considered contralateral.
C	Both statements are true. Structures on the same side of the body are considered ipsilateral. Structures on the opposite side of the body are considered contralateral.
D	Both statements are true. Structures on the same side of the body are considered ipsilateral. Structures on the opposite side of the body are considered contralateral.

DIF: Recall REF: p. 3 OBJ: 1
TOP: CDA: General Chairside, I. A. Demonstrate understanding of basic oral and dental anatomy, physiology, and development
MSC: NBDHE, Scientific Basis for Dental Hygiene Practice, 1.1 Anatomy

15. The number of bones and muscles in the head and neck is NOT usually constant, and specific details of these structures can vary from patient to patient.
- Both statements are true.
 - Both statements are false.
 - The first statement is true; the second is false.
 - The first statement is false; the second is true.

ANS: D

Feedback	
A	The first statement is false; the second is true. The number of bones and muscles in the head and neck is usually constant, but specific details of these structures can vary from patient to patient.
B	The first statement is false; the second is true. The number of bones and muscles in the head and neck is usually constant, but specific details of these structures can vary from patient to patient.
C	The first statement is false; the second is true. The number of bones and muscles in the head and neck is usually constant, but specific details of these structures can vary from patient to patient.
D	The first statement is false; the second is true. The number of bones and muscles in the head and neck is usually constant, but specific details of these structures can vary from patient to patient.

DIF: Comprehension REF: p. 3 OBJ: 3
TOP: CDA: General Chairside, I. B. Preliminary Physical Examination
MSC: NBDHE, Provision of Clinical Dental Hygiene Services, 1.0 Assessing Patient Characteristics

16. The median plane is created by an imaginary line dividing the body into equal right and left halves. On the surface of the body, these halves are NEVER symmetric in structure.
- Both statements are true.
 - Both statements are false.
 - The first statement is true; the second is false.
 - The first statement is false; the second is true.

ANS: C

Feedback	
A	The first statement is true; the second is false. The median plane or midsagittal plane is created by an imaginary line dividing the body into equal right and left halves. On the surface of the body, these halves are generally symmetric in structure, yet the same symmetry does NOT apply to all internal structures.
B	The first statement is true; the second is false. The median plane or midsagittal plane is created by an imaginary line dividing the body into equal right and left halves. On the surface of the body, these halves are generally symmetric in structure, yet the same symmetry does NOT apply to all internal structures.
C	The first statement is true; the second is false. The median plane or midsagittal plane is created by an imaginary line dividing the body into equal right and left halves. On the surface of the body, these halves are generally symmetric in structure, yet the same symmetry does NOT apply to all internal structures.
D	The first statement is true; the second is false. The median plane or midsagittal plane is created by an imaginary line dividing the body into equal right and left halves. On the surface of the body, these halves are generally symmetric in structure, yet the same symmetry does NOT apply to all internal structures.

DIF: Recall REF: p. 3 OBJ: 2

TOP: CDA: General Chairside, I. A. Demonstrate understanding of basic oral and dental anatomy, physiology, and development

MSC: NBDHE, Scientific Basis for Dental Hygiene Practice, 1.1 Anatomy

17. An area closer to the median plane of the body or structure is considered lateral. An area farther from the median plane of the body or structure is considered proximal.
- Both statements are true.
 - Both statements are false.
 - The first statement is true; the second is false.
 - The first statement is false; the second is true.

ANS: B

Feedback	
A	Both statements are false. An area closer to the median plane of the body or structure is considered medial. An area farther from the median plane of the body or structure is considered lateral, and an area closer to the median plane is considered to be proximal.
B	Both statements are false. An area closer to the median plane of the body or structure is considered medial. An area farther from the median plane of the body or structure is considered lateral, and an area closer to the median plane is considered to be proximal. Within the dentition, the proximal surface would be considered mesial.
C	Both statements are false. An area closer to the median plane of the body or structure is considered medial. An area farther from the median plane of the body or structure is considered lateral, and an area closer to the median plane is considered to be proximal.
D	Both statements are false. An area closer to the median plane of the body or structure is considered medial. An area farther from the median plane of the

	body or structure is considered lateral, and an area closer to the median plane is considered to be proximal.
--	---

DIF: Recall REF: p. 3 OBJ: 2
 TOP: CDA: General Chairside, I. A. Demonstrate understanding of basic oral and dental anatomy, physiology, and development
 MSC: NBDHE, Scientific Basis for Dental Hygiene Practice, 1.1 Anatomy

18. What is another term for *coronal plane*?
- Frontal plane
 - Coronal section
 - Horizontal plane
 - Horizontal section

ANS: A

Feedback	
A	A frontal plane or coronal plane is created by an imaginary line dividing the body at any level into both anterior and posterior parts.
B	The frontal plane or coronal section is a division through any frontal plane.
C	A horizontal plane is created by an imaginary line dividing the body at any level into superior and inferior parts and is always perpendicular to the median plane.
D	The transverse section or horizontal section is a division through a horizontal plane.

DIF: Recall REF: p. 3 OBJ: 1
 TOP: CDA: General Chairside, I. A. Demonstrate understanding of basic oral and dental anatomy, physiology, and development
 MSC: NBDHE, Scientific Basis for Dental Hygiene Practice, 1.1 Anatomy

19. Muscles may differ in size and details of their attachments. Joints, vessels, nerves, glands, lymph nodes, fasciae, and spaces of an individual can vary in size, location, and even presence.
- Both statements are true.
 - Both statements are false.
 - The first statement is true; the second is false.
 - The first statement is false; the second is true.

ANS: A

Feedback	
A	Both statements are true. Muscles may differ in size and details of their attachments. Joints, vessels, nerves, glands, lymph nodes, fasciae, and spaces of an individual can vary in size, location, and even presence.
B	Both statements are true. Muscles may differ in size and details of their attachments. Joints, vessels, nerves, glands, lymph nodes, fasciae, and spaces of an individual can vary in size, location, and even presence.
C	Both statements are true. Muscles may differ in size and details of their attachments. Joints, vessels, nerves, glands, lymph nodes, fasciae, and spaces of an individual can vary in size, location, and even presence.

D	Both statements are true. Muscles may differ in size and details of their attachments. Joints, vessels, nerves, glands, lymph nodes, fasciae, and spaces of an individual can vary in size, location, and even presence.
----------	--

DIF: Comprehension

REF: p. 3

OBJ: 3

TOP: CDA: General Chairside, I. A. Demonstrate understanding of basic oral and dental anatomy, physiology, and development

MSC: NBDHE, Scientific Basis for Dental Hygiene Practice, 1.1 Anatomy

20. What is another term for *midsagittal plane*?
- Median plane
 - Coronal plane
 - Frontal plane
 - Horizontal plane

ANS: A

Feedback	
A	The median plane or midsagittal plane is created by an imaginary line dividing the body into equal right and left halves.
B	A frontal plane or coronal plane is created by an imaginary line dividing the body at any level into anterior and posterior parts.
C	A frontal plane or coronal plane is created by an imaginary line dividing the body at any level into anterior and posterior parts.
D	A horizontal plane is created by an imaginary line dividing the body at any level into superior and inferior parts and is always perpendicular to the median plane.

DIF: Recall

REF: p. 3

OBJ: 1

TOP: CDA: General Chairside, I. A. Demonstrate understanding of basic oral and dental anatomy, physiology, and development

MSC: NBDHE, Scientific Basis for Dental Hygiene Practice, 1.1 Anatomy

21. A horizontal plane is created by an imaginary line dividing the body at any level into both superior and inferior parts and is ALWAYS _____ to the median plane.
- anterior
 - posterior
 - parallel
 - perpendicular

ANS: D

Feedback	
A	A frontal plane or coronal plane is created by an imaginary line dividing the body at any level into both anterior and posterior parts. A horizontal plane is created by an imaginary line dividing the body at any level into both superior and inferior parts and is always perpendicular to the median plane.
B	A frontal plane or coronal plane is created by an imaginary line dividing the body at any level into both anterior and posterior parts. A horizontal plane is created by an imaginary line dividing the body at any level into both superior and inferior parts and is always perpendicular to the median plane.